



Case Report

Paederus Dermatitis in Cambodia

Chendavatey Pok*, Savoeurn Pok, Channa Prum

Pok Savoeurn Dermatology Clinic

Received: September 19, 2024; revised 24, 2024; accepted November 04, 2024

ABSTRACT

Introduction

Paederus dermatitis (PD) is an irritant contact dermatitis (ICD) triggered by a beetle from the genus *Paederus*, which is a part of Staphylinidae family. PD, also referred to as dermatitis linearis, is a condition caused by the toxin released from the beetles. Rarely but when this insect bites or stings, the fluid released from this beetle usually contains pederine. It is a potent toxin found inside these insects' body fluids. It can lead from erythematous to vesicular lesions, blisters, and a burning/pain sensation on the exposed areas of the body.

Case Presentation

In this setting, we reported two cases of 35-year-old and 30-year-old Cambodian males who presented with an abrupt burning sensation, itchy oozing rash, streaky linear lesion, and kissing lesions. A short course of oral corticosteroids, topical antibiotics, steroid cream, and bar soap were prescribed to treat symptoms. The prognosis is favorable and the recovery is self-limiting within 7-10 days.

Conclusion

Even though PD has a small outbreak, it should not be overlooked especially during the rainy season. Healthcare personnel should not only focus on the disease but also need to be aware of the patient's surrounding environment. Although the disease is self-limiting, it can cause tremendous discomfort to patients. Education and prevention should be put out to raise awareness of this condition.

*Corresponding author: Dr. Chendavatey POK at Email: pok_chenda_vatey@yahoo.com, #17, Street 213, Sangkat Veal Vong, Khan 7 Makara, Phnom Penh

Citation: Pok, C, Pok S, Prum C. Case Report of Paederus Dermatitis in Cambodia, *CJPH* (2024) 05:09

© 2024 Cambodia Journal of Public Health. All rights reserved

Keywords: Paederus dermatitis, Pederin, Arthropods, Beetle, Irritant contact dermatitis

Introduction

Paederus dermatitis (PD) is a specific type of irritant contact dermatitis (ICD) triggered by a beetle from the genus *Paederus*, which is a part of Staphylinidae family [1]. The hemolymph of some rove beetles in the *Paederus* genus contains the vesicant pederin, which is thought to be produced by endosymbiotic bacteria [2]. There are around 1.5 million species living on earth, yet the beetles are accountable for 25% of all described species [3]. PD also referred to as dermatitis linearis, is a condition caused by the toxin released from the above-mentioned arthropod [4]. Rarely does this insect bite or sting, yet the fluid released from this beetle usually contains pederine, a potent vesicant agent [1]. The toxin inside these insects' body fluids can lead from erythematous to vesicular/bullae lesions, and a burning/pain sensation on the exposed areas of the body [4]. According to Kumaraguru et al., these insects are usually 7-10 mm long and are distinguished by vivid orange or red stripes on the pronotum and the base of the abdominal segments (Figure 1). People tend to confuse the *Paederus* beetles with ants. These insects are capable of flying, but they still prefer to crawl and exhibit phototaxis to fluorescent light, specifically a long wavelength white light. Additionally, Kumaraguru and his colleagues observed that the beetles tend to curl up their abdomen when running or being disturbed, which may indicate why they are easily crushed due to their vulnerability [4].



Figure 1. Adult *Paederus* beetles with length and width between 7-10 mm long and 0.5-1 mm wide. They have a black head, a thorax, an upper abdomen, a lower abdomen, and an elytrum (Structuring covering the wings) [8]

Furthermore, the prevalence of PD has been reported during the period of increased rainfall [9]. Importantly, Cambodia is a country with a tropical climate that usually attracts rainfall, in which causes many incidences of PD. Due to this reason, we are here to report cases concerning cutaneous findings related to PD.

Case Presentation

Case 1

A 35-year-old Cambodian male patient complained of an abrupt burning sensation and itchy rash oozing on his right forearm for two days. The patient denied a history of past medical illness, hospitalization, surgery, and allergy. The physical examination marked a healthy man with good consciousness, normal vital signs, no pallor, and no jaundice. The cutaneous findings were a bizarre linear edematous and erythematous rash unilaterally on the right forearm upon inspection (**Figure 2&3**). The patient did not receive further laboratory investigation due to the obvious cutaneous presentation and the evidence of having crushed the beetles with his hands.

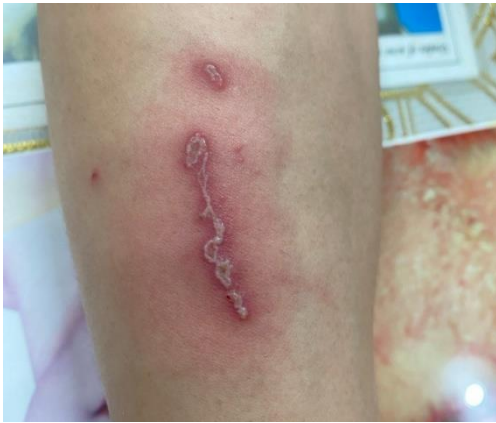

Figure 2. Case 1- ICD in a linear pattern caused by *Paederus* beetles on the right forearm.

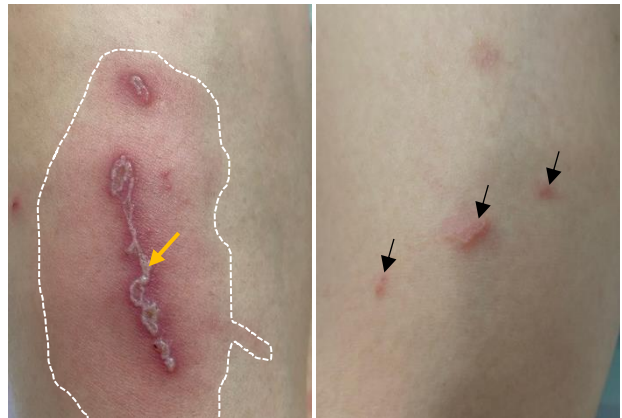


Figure 3. Case 1- A close-up view. A well-defined edematous and erythematous border (white dashed line). A linear coalescent vesicular lesion (yellow arrow). Erythematous papules from mild irritant toxin (black arrows).

Regarding his management, he received topical erythromycin 4% solution to prevent superimposed bacterial infection, betamethasone valerate cream (0.05%) to minimize the inflammation, and Harrogate Sulphur soap to disinfect the bacteria in the affected regions. All of the topical medications were applied twice a day until the recovery. The prognosis is favorable because the cause of the culprit is exogenous.

Case 2

A 30-year-old Cambodian male patient experienced itchy oozing rashes, burning sensation, and localized pain at the right antecubital fossa for four days. The physical examination marked a patient with good consciousness and normal vital signs except for cutaneous findings. He denied underlying disease, past history, or familial history of this type of disease onset. On dermatologic examination, the patient presented with unilateral kissing lesions with vesicles, pustules, and central necrotic bullae surrounded by well-defined erythematous lesions (**Figure 4&5**).

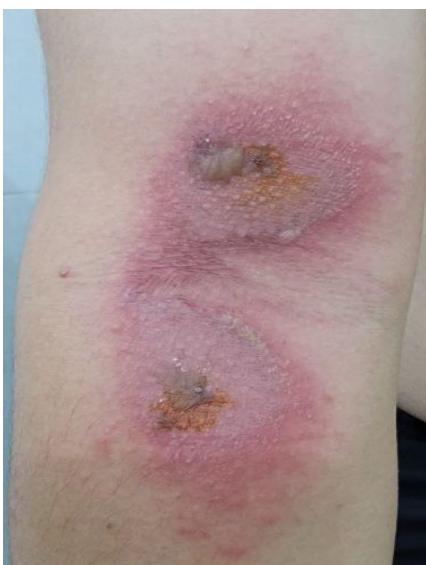

Figure 4. Case 2- A moderate ICD from exposure of a *Paederus* beetle toxin formed a kissing lesion on the right antecubital fossa.

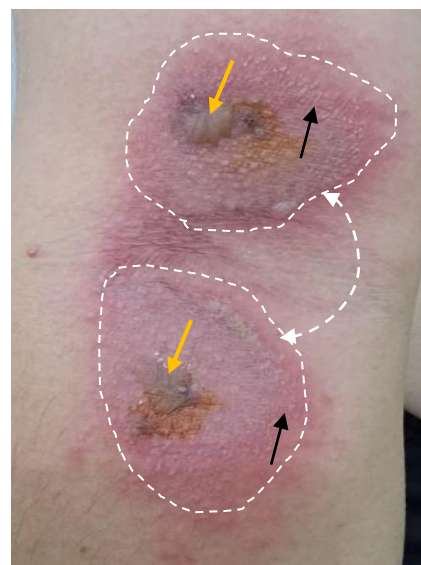


Figure 5. Case 2- A close-up view. A well-defined kissing lesion (white dashed line). Central necrotic bullae (yellow arrow). Vesicles (black arrow).

Discussion

The typical cutaneous presentations caused by the rove beetles include “streaky vesiculopustular eruption”, “kissing lesions”, and “Nairobi eye” [2]. Bear in mind that *Paederus* beetles are different from blister beetles, which belong to another family called Meloidae. These blister beetles are also widely distributed but release a different toxin called cantharidin [10]. The *Paederus* beetles are good insects for agriculture due to the fact that they ingest crop pests. They typically inhabit in a moist environment which is why there are more cases reported during the rainy season. A study from Thailand in 2007 reported that approximately 91% of military personnel who worked in Bangkok experienced PD between April and May 2007 [11]. Moreover, in one study in Manipal, India where 100 patients consulted OPD with PD, 59% had overgrown gardens around their houses and 17% of patients liked to sleep with a light on, while the majority (89%) slept on the floor [12]. A similar report was also found among scholars who attended night tutoring in Malaysia [4]. Paederine is a strong toxin with the potential to cause a cutaneous reaction after the exposure within 24 hours. Different levels of cutaneous clinical signs and severity depend on the toxin concentration, exposure duration, and individual’s biological characteristics [13]. In mild exposure, there will be light erythema lasting only for a couple of days. In moderate exposure, the erythema will develop into vesicles and bullae over a few days and later followed by desquamation and hyper- or hypopigmented patches. Scarring rarely occurs. In severe cases, extensive blistering associated with additional symptoms, such as fever, neuralgia, arthralgia, and vomiting will be observed [14,15]. The study by Uzunoğlu et al., found that their patients were commonly presented with erythematous plaques (84.8%), pustules, erosion (23.9%), vesicles (13.0%), and dermatitis linearis (47.8%) [9]. The patients commonly received nonsteroidal anti-inflammatory drugs (NSAIDs) for the pain, and the topical steroids in combination with antibiotics. These findings were consistent with the case reports’ management. Most importantly, PD can be easily misdiagnosed due to its similar clinical manifestation to other viral or bacterial cutaneous diseases such as bullous impetigo, herpes simplex, and herpes zoster. In the context of contact dermatitis, allergic contact dermatitis, liquid burns, and phytodermatitis should be well differentiated before jumping into the diagnosis of PD [16]. The limitation of the case was that the patient did not receive further laboratory investigation to rule out other diseases with the same pattern due to the physician’s certainty over PD characteristics. Due to the limited data related to PD in Cambodia, a larger cross-sectional study should be conducted to observe the outbreak of PD during the rainy season.

Conclusions

PD is rarely reported in Cambodia but is a common skin disease encountered by dermatologists with different clinical presentations. Even though PD has a small outbreak, it should not be overlooked especially during this rainy season. Healthcare personnel should not only focus on the disease but also need to be aware of the patient’s surrounding environment and habitat. Although the disease is spontaneous recovery, it can cause tremendous distress to the patients. Education and prevention should be put out to raise awareness of this condition. Identifying the beetles and refraining from touching or crushing them can help reduce the occurrence of eruptions. If a beetle lands on your skin, gently blow it off or guide it onto a piece of paper before removing it. Wash the affected area with soap and water right away. To minimize beetle entry, keep doors closed and turn off lights when people are sleeping.

Acknowledgments

Great appreciation to Dr. Savoeurn Pok for collecting documents and arranging the appointments for the case reports.

Contribution

Dr. Chendavatey Pok, Dr. Savoeurn Pok, and Dr. Channa Prum were responsible for the writing of this manuscript.

Declaration

There is no conflict of interest. Informed consents were obtained from the patients.

References

- [1] Mammino JJ. Paederus Dermatitis. *J Clin Aesthet Dermatol* [Internet]. 2011 Nov [cited 2023 Mar 9];4(11):44–6. Available from: <https://www.ncbi.nlm.nih.gov/pmc/articles/PMC3225135/>
- [2] Bologna JL, Schaffer J, Cerroni L. *Dermatology: ExpertConsult*. 4th ed. Edinburgh: Elsevier; 2017. 2880 p.
- [3] Stork NE, McBroom J, Gely C, Hamilton AJ. New approaches narrow global species estimates for beetles, insects, and terrestrial arthropods. *Proc Natl Acad Sci U S A* [Internet]. 2015 Jun 16 [cited 2023 Mar 9];112(24):7519–23. Available from: <https://www.ncbi.nlm.nih.gov/pmc/articles/PMC4475949/>
- [4] Kumaraguru A, Ramalingam R, Thangaraj P, Seethalakshmi RS, Balasubramanian N. Clinico-dermatologic patterns of Paederus dermatitis in a teaching hospital, South India. *J Family Med Prim Care* [Internet]. 2022 Aug [cited 2023 Feb 22];11(8):4357–62. Available from: <https://www.ncbi.nlm.nih.gov/pmc/articles/PMC9638569/>
- [5] Şanlı Erdoğan B, Ergin Ş, Aktan Ş, Kaçar N. Denizli Yöresinden Paederus Dermatiti Olguları. [cited 2023 Mar 9];40(4):123–5. Available from: <https://jag.journalagent.com/z4/vi.asp?pdid=turkderm&plng=tur&un=TURKDERM-02996&look4=>
- [6] Vanhecke C, Malvy D, Guevart E, Laloge V, Ezzedine K. [Paederus dermatitis: A retrospective study of 74 cases occurring in 2008 in Guinea-Conakry]. *Ann Dermatol Venereol*. 2010 Mar;137(3):189–93.
- [7] Bong LJ, Neoh KB, Jaal Z, Lee CY. Influence of temperature on survival and water relations of Paederus fuscipes (Coleoptera: Staphylinidae). *J Med Entomol*. 2013 Sep;50(5):1003–13.
- [8] Paederinae. In: Wikipedia [Internet]. 2023 [cited 2023 Mar 10]. Available from: <https://en.wikipedia.org/w/index.php?title=Paederinae&oldid=1133023608>
- [9] Uzunoğlu E, Oguz ID, Kir B, Akdemir C. Clinical and Epidemiological Features of Paederus Dermatitis Among Nut Farm Workers in Turkey. *Am J Trop Med Hyg* [Internet]. 2017 Feb 8 [cited 2023 Mar 9];96(2):483–7. Available from: <https://www.ncbi.nlm.nih.gov/pmc/articles/PMC5303057/>
- [10] Frank JH, Kanamitsu K. Paederus, sensu lato (Coleoptera: Staphylinidae): natural history and medical importance. *J Med Entomol*. 1987 Mar;24(2):155–91.
- [11] Suwannahitatorn P, Jatapai A, Rangsin R. An outbreak of Paederus dermatitis in Thai military personnel. *J Med Assoc Thai*. 2014 Feb;97 Suppl 2:S96-100.
- [12] Taneja A, Uk SN, Sheno SD. Clinical and epidemiological study of Paederus dermatitis in Manipal, India. *Journal of Pakistan Association of Dermatologists* [Internet]. 2013 [cited 2023 Mar 10];23(2):133–8. Available from: <https://www.jpada.com.pk/index.php/jpad/article/view/295>
- [13] Piel J. A polyketide synthase-peptide synthetase gene cluster from an uncultured bacterial symbiont of Paederus beetles. *Proc Natl Acad Sci U S A* [Internet]. 2002 Oct 29 [cited 2023 Mar 10];99(22):14002–7. Available from: <https://www.ncbi.nlm.nih.gov/pmc/articles/PMC137826/>
- [14] Borroni G, Brazzelli V, Rosso R, Pavan M. Paederus fuscipes dermatitis. A histopathological study. *Am J Dermatopathol*. 1991 Oct;13(5):467–74.
- [15] Qadir SNR, Raza N, Rahman SB. Paederus dermatitis in Sierra Leone. *Dermatol Online J*. 2006 Dec 10;12(7):9.
- [16] Huang C, Liu Y, Yang J, Tian J, Yang L, Zhang J, et al. An outbreak of 268 cases of Paederus dermatitis in a toy-building factory in central China. *Int J Dermatol*. 2009 Feb;48(2):128–31.